

한국인 정상안 맥락막의 일중변동

Diurnal Variation of the Choroid in Normal Korean Subjects

성산, 김양재, 김주영, 이진해, 오현섭, 김순현, 권오웅, 유용성

San Seong, Yang Jae Kim, Ju Young Kim, Jin Hae Lee, Hyun Sup Oh, Soon Hyun Kim, Oh Woong Kwon, Yong Sung You

누네안과병원 망막센터

Retina Center, Nune Eye Hospital, Seoul, Korea

Purpose: To determine the diurnal variation in choroidal thickness and choriocapillaris flow measured by optical coherence tomography (OCT) and optical coherence tomography angiography (OCTA)

Methods: This study was a prospective study of 15 normal, young volunteers (30 eyes) who underwent OCT and OCTA examination 5 times a day at 2-hour intervals. Choroidal and choriocapillaris thicknesses were measured with the enhanced depth imaging mode of OCT. The area of flow was measured in 1-, 3-, and 6-mm-diameter areas centered at the fovea and analyzed with the split-spectrum amplitude-decorrelation angiography algorithm of OCTA. Choroidal and choriocapillaris thicknesses and flows were analyzed independently by two vitreoretinal specialists.

Results: Choroidal thickness showed a significant diurnal variation. The maximum thickness was 311.31 μm at 9 a.m., and the minimum thickness was 266.75 μm at 5 p.m. ($p < 0.001$). In contrast, the mean choriocapillaris thickness was 15.14 μm , and remained relatively constant without a significant diurnal variation ($p = 0.694$). The mean choriocapillaris flow area was 0.45 mm^2 ($p = 0.238$) in a 1 mm area, 4.22 mm^2 ($p = 0.230$) in a 3-mm diameter area, and 16.94 mm^2 ($p = 0.062$) in a 6-mm diameter area. No diurnal variation was observed.

Conclusions: Despite significant diurnal variation in choroidal thickness, choriocapillaris thickness and flow remained relatively constant over time.

Keywords: Choriocapillaris; Optical coherence tomography; Optical coherence tomography angiography

Introduction

The choroid is a tissue located below the retinal pigment epithelium that supplies blood to the outer retina. Spaide et al. [1] measured its thickness with the enhanced depth imaging (EDI) technique first made possible by spectralis optical coherence tomography (OCT) (Spectralis; Heidelberg

Engineering, Heidelberg, Germany) [2]. Later, many studies reported that increased choroidal thickness and choroidal vascular abnormalities are associated with pachychoroid spectrum disorders, including central serous chorioretinopathy, pachychoroid pigment epitheliopathy, and pachychoroid neovascularopathy [3-6]. Consequently, interest in the choroid has increased [7-10].

Address reprint requests to Yong Sung You, MD, PhD

Department of Ophthalmology, Nune Eye Hospital, #404 Seolleung-ro, Gangnam-Gu, Seoul 06198, Korea
Tel: +82-2-2086-7752, Fax: +82-2-2086-7779
E-mail: yongsung.you@gmail.com

Received: 2018. 8. 6
Revised: 2018. 8. 21
Accepted: 2018. 8. 23

To understand changes in the choroid, normal choroid characteristics need to be assessed. Tan et al. [11] analyzed and reported diurnal variation in choroidal thickness in normal healthy subjects. Almeida et al. [9] compared changes in choriocapillaris thickness between healthy participants and patients with intermediate age-related macular degeneration (AMD) in seated and supine positions. According to these reports, normal choroidal thickness ranges from 191.5 to 342 μm and is affected by age, axial length, refractive error, systolic blood pressure, the time it is measure [1,2,12]. The choriocapillaris was significantly thicker in patients with intermediate AMD than in healthy participants and significantly thinner in the supine than the seated position [11].

Changes in choroidal and choriocapillaris thickness in healthy subjects have been analyzed in many studies, but diurnal variations in choroidal and choriocapillaris thickness has yet to be studied along with choriocapillaris flow. Recently, OCT angiography (OCTA) (Avanti RTVue XR; Optovue Inc., Fremont, CA, USA), which noninvasively measures red blood cell migration in retinal and choroidal vessels over time was introduced to measure blood vessel structure and blood flow quickly and easily. The results are shown as an OCT B-Scan [13]. The choriocapillaris exhibits a homogenous appearance with a bright, flow area; a dark, low flow area; or empty space [14]. Al-Sheikh et al. [15,16] quantified features of the choriocapillaris with OCTA in healthy subjects and reported good reproducibility.

Changes in choriocapillaris thickness and flow in each chorioretinal disease seem to correlate with changes in choroidal thickness. Analyzing normal values may help determine the relationship between choroidal thickness and disease. In this study, we analyzed changes in the choroid and choriocapillaris thickness and choriocapillaris flow over time with OCT and OCTA in young healthy subjects.

Materials and Methods

This was a prospective study of 30 eyes of 15 healthy, young adults with no known ophthalmic or systemic disease. Spectral-domain OCT and OCTA scans were performed 5 times from 9 a.m. to 5 p.m. at 2-hour intervals at the Retina Center of Nune Eye Hospital in Seoul, South Korea. The study protocol was approved by the Institutional Review Board of Nune Eye Hospital (IRB No. N-1807-001-999), and the study

was conducted in accordance with the tenets of the Declaration of Helsinki. Informed consent was obtained from all study participants.

All subjects received an ophthalmologic examination to rule out ophthalmic diseases, and the same experienced operator conducted spectral-domain OCT and OCTA with an dilated pupil five times in a day at 2-hour intervals (9:00 a.m., 11:00 a.m., 1:00 p.m., 3:00 p.m., and 5:00 p.m.).

For OCT, high-quality horizontal and vertical line scans involving the fovea were performed at the same site in EDI mode with the eye tracking system, based on the 9 a.m. scan.

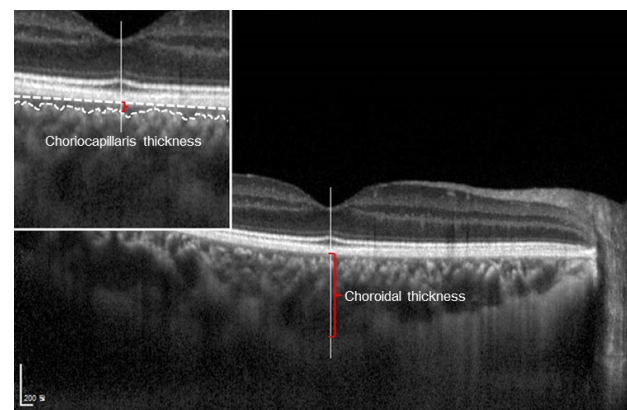


Figure 1. Example of choroidal and choriocapillaris thickness measurement.

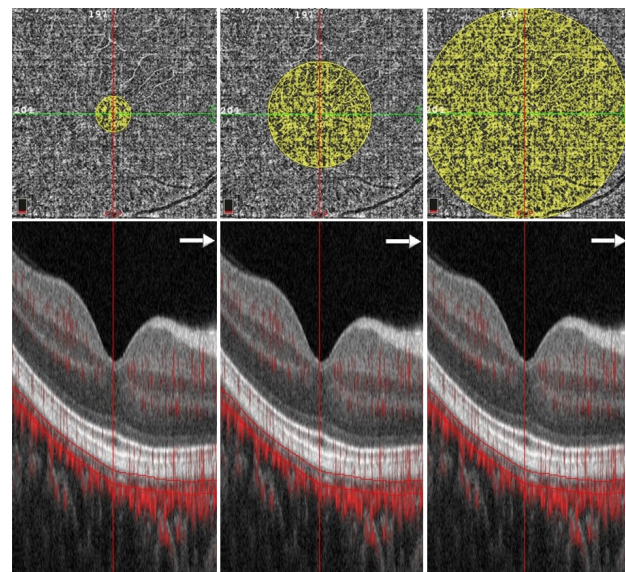


Figure 2. Examples of choriocapillaris flow area measurement (diameter: 1, 3, 6 mm).

Subfoveal choroidal thickness was the distance between vertical caliper lines drawn at the hyperreflective retinal pigment epithelium (RPE) line under the fovea and the chorioid-scleral junction, measured with manual calipers using proprietary software (Heidelberg Eye Explorer; Heidelberg Engineering, Heidelberg, Germany) (Fig. 1). Subfoveal choriocapillaris thickness was the distance between the RPE line under the fovea and the upper border of Sattler's layer measured with the same method (Fig. 1).

OCTA scanning was done with the split-spectrum amplitude-decorrelation angiography algorithm (SSADA), and the flow area of the choriocapillaris was measured in 1-, 3-, and 6-mm diameter areas centered on the fovea in the B-scan through autosegmentation of the installed program (Fig. 2). In all subjects, the axial length (IOL Master 500; Carl Zeiss Meditec, Dublin, CA, USA) and refractive error (Autorefractor KR-800A; Topcon, Oakland, CA, USA) were measured before the first OCT and OCTA scan. Two independent vitreoretinal specialists (S.S and Y.S.Y) carried out the mea-

surements without knowledge of the subject's information. To assess intraobserver variability, each examiner performed three repeated measurements on one subject. No statistically significant difference was observed among these measurements ($p > 0.05$).

For statistical analysis, repeated-measures ANOVA was performed with IBM SPSS for Windows (version 21.0; SPSS Inc., Chicago, IL, USA), and $p < 0.05$ was considered statistically significant.

Results

A total of 30 eyes (15 patients: 7 males, 8 females) were enrolled. The mean age was 26.58 ± 5.27 years (range: 21-38 years). The mean systolic blood pressure right before the first OCT and OCTA scan was 112.11 ± 6.51 mmHg (range: 104-129 mmHg), and the mean diastolic blood pressure was 71.44 ± 4.94 mmHg (range: 63-82 mmHg). The mean axial length was 24.42 ± 0.95 mm (range: 23.00-26.89 mm), and the mean spherical equivalent was -2.49 ± 2.08 D (range: -6.75 to +0.5 D) (Table 1). The mean baseline subfoveal choroidal thickness measured at 9:00 a.m. was 311.31 ± 97.41 μ m (range: 140-465 μ m), and the mean baseline subfoveal choriocapillaris thickness was 15.13 ± 1.09 μ m (range: 13.00-17.00 μ m) (Table 2).

The subfoveal choroid was thickest at 9:00 a.m. (311.31 μ m), and the thickness decreased linearly and gradually with time, reaching a minimum thickness of 266.75 μ m at 5:00 p.m. The mean diurnal variation was 44.56 ± 19.88 μ m (range: 17-71 μ m), which was a significant difference ($p < 0.001$) (Table 2).

The subfoveal choriocapillaris thickness was also analyzed. The mean choriocapillaris thickness measured at 9:00

Table 1. Demographics of participants

	Value
Sex (male:female)	15 patients (7:8)
Age (years)	26.58 ± 5.27 (21-38)
Axial length (mm)	24.42 ± 0.95 (23.00-26.89)
Spherical equivalent (D)	-2.49 ± 2.08 (-6.75 to +0.5)
Blood pressure (mmHg)	
SBP	112.11 ± 6.51 (104-129)
DBP	71.44 ± 4.94 (63-82)

Values are presented as mean \pm standard deviation (range) unless otherwise indicated.

SBP = systolic blood pressure; DBP = diastolic blood pressure.

Table 2. Diurnal variation in the choroidal and choriocapillaris thickness and choriocapillaris flow area

	9:00 a.m.	11:00 a.m.	1:00 p.m.	3:00 p.m.	5:00 p.m.	<i>p</i> -value*
Choroidal thickness (μ m)	311.31	299.81	291.38	281.06	266.75	< 0.001
Choriocapillaris thickness (μ m)	15.13	15.25	15.13	15.19	15.00	0.694
Choriocapillaris flow area (diameter) (mm ²)						
1 mm	0.46	0.45	0.45	0.46	0.45	0.238
3 mm	4.26	4.22	4.22	4.21	4.19	0.230
6 mm	17.11	16.96	16.93	16.89	16.78	0.062

* $p < 0.05$ was considered statistically significant.

Table 3. Factors affecting diurnal variation in choroidal thickness

	Variation in choroidal thickness (μm)	<i>p</i> -value*
Axial length (mm)		< 0.001
≤ 23.5	43.4	
> 23.5	21.6	
Spherical equivalent (D)		< 0.001
> -0.5	41.7	
≤ -0.5	13.5	

* $p < 0.05$ was considered statistically significant.

a.m. was $15.13 \pm 1.09 \mu\text{m}$ (range: 13-17 μm), at 11:00 a.m. was $15.25 \pm 1.29 \mu\text{m}$ (range: 13-18 μm), at 1:00 p.m. was $15.13 \pm 1.36 \mu\text{m}$ (range: 12-17 μm), at 3:00 p.m. was $15.19 \pm 1.33 \mu\text{m}$ (range: 12-17 μm), and at 5:00 p.m. was $15.00 \pm 0.97 \mu\text{m}$ (range: 13-17 μm). These measurements did not vary significantly ($p = 0.694$) (Table 2). The diurnal variation from baseline values correlated significantly with axial length (Pearson correlation coefficient -0.572, $p < 0.001$), refractive error (spherical equivalent) (Pearson correlation coefficient 0.638, $p < 0.001$), and systolic blood pressure (Pearson correlation coefficient 0.602, $p = 0.024$) (Table 3).

The mean baseline flow area of the subfoveal choriocapillaris measured by OCTA was $0.45 \pm 0.03 \text{ mm}^2$ (range: 0.37-0.51 mm^2) ($p = 0.238$) in a 1-mm area centered on the fovea, $4.22 \pm 0.11 \text{ mm}^2$ (range: 3.90-4.46 mm^2) ($p = 0.230$) in a 3-mm area, and $16.94 \pm 0.42 \text{ mm}^2$ (range: 15.70-17.78 mm^2) ($p = 0.062$) in a 6-mm area, exhibiting no significant diurnal variation (Table 2).

Discussion

As previously reported, diurnal variation occurs in normal eyes, in which the subfoveal choroid is thickest in the morning and decreases significantly and linearly over time. The same pattern was observed in the present study. The subfoveal choriocapillaris thickness and choriocapillaris flow area remained constant from morning through afternoon [11].

In a study conducted by Kim et al. [17], the mean subfoveal choroidal thickness was $307.26 \pm 95.18 \mu\text{m}$ in healthy Koreans with a mean age of 40.18 ± 17.89 years, showing a significant positive correlation with refractive error and

a significant negative correlation with age. In the present study, the mean subject age was 26.13 ± 5.24 years (range: 21-38 years). The subjects had a subfoveal choroidal thickness of $290.06 \pm 90.92 \mu\text{m}$, which is similar to the mean subfoveal choroidal thickness of $287 \pm 76 \mu\text{m}$ reported in a Western population and lower than the $354 \pm 111 \mu\text{m}$ reported in a Japanese population [2,18].

Tan et al. [11] reported that diurnal variation in subfoveal choroidal thickness differed depending on the region. The variation differed significantly according to baseline subfoveal choroidal thickness, while age, axial length, refractive error, and change in systolic blood pressure were significantly correlated with the range of diurnal variation in thickness. In the present study, the baseline subfoveal choroidal thickness was significantly positively correlated with the range of diurnal variation, while baseline values differed significantly depending on axial length, refractive error, and change in systolic blood pressure.

Almeida et al. [9] analyzed choriocapillaris thickness by position in healthy subjects and patients with intermediate AMD, and it was significantly thicker in patients with AMD. Choriocapillaris was also significantly thinner in the supine position than in the seated position [9]. These results validate the observation that both choroidal and choriocapillaris thicknesses are affected by various conditions. Therefore, the present study analyzed diurnal variation in subfoveal choriocapillaris thickness in healthy subjects and confirmed that it was constant, exhibiting no significant difference from the baseline measured at 9:00 a.m.

The present study also analyzed diurnal variation by measuring the flow density of the choriocapillaris with OCTA. Al-Sheikh et al. [15,16] reported choriocapillaris flow characteristics by analyzing the grey value with Image J software (National Institute of Health, Bethesda, MD, USA). Choriocapillaris flow was quantified a swept-source OCTA device (DRI OCT Triton; Topcon, Tokyo, Japan) in healthy individuals. In addition, Wang et al. [19] quantified vessel density by measuring choriocapillaris vessel diameter and pixel density after randomly selecting 57 areas in a 1-mm-diameter circle and 155 areas in a 3-mm-diameter circle centered on the fovea in healthy eyes. We measured the autosegmentation of the choriocapillaris and its flow area in healthy individuals by using the software installed in the swept-source OCTA device (Avanti RTVue XR; Optovue Inc., Fremont, CA, USA). As a result, the choriocapillaris flow areas calcu-

lated in 1-, 3-, and 6-mm-diameter circles were maintained without significant change from the flow area measured at 9:00 a.m.

The limitations of the present study are as follows. The sample size was small, the age range was limited to young subjects, and diurnal variation in the choroid and choriocapillaris according to age could not be analyzed. We did not analyze the effects on choroid and choriocapillaris that could occur due to sustaining an upright position for a day. Moreover, choroidal and choriocapillaris thicknesses were measured only at one point in the subfoveal area; thus, the change in overall choroidal vasculature could not be assessed. In addition, since the analysis was performed based on measurements done five times in a day, the change at time points other than the measurement time points could not be analyzed, and hormonal changes (e.g., menstruation) that are considered to affect the choroid were not analyzed. Spectralis OCT scanning generates 40,000 A-scans/second with an axial resolution of 3.5 μm /pixel digital and a transverse resolution of 14 μm [20]. The average choriocapillaris thickness in this study was 15.14 μm . The minimum thickness was 13.00 μm , and the maximum thickness was 17.00 μm according to measurement time. Confirming that the change over time does not meet the axial resolution of OCT is difficult. However, this effect would not explain the statistically significant differences. As autosegmentation was performed by software installed in OCTA to analyze the choriocapillaris flow area, segmentation errors may have occurred, and some low flows might have not been measured due to the OCTA algorithm itself, to remove the projection artifact.

The present study, however, provides comparison criteria for diseased eyes because normal choroidal and choriocapillaris thicknesses and choriocapillaris flow areas were analyzed. These measurements are considered to play an important role in the pathophysiology of various ophthalmic diseases. In addition, the choriocapillaris thickness and flow area were constant, unlike choroidal thickness, which suggests a physiological role of the choriocapillaris for constantly supplying oxygen and nutrients to the outer retina.

In conclusion, the present study is significant in that it analyzed diurnal variation in choroidal and choriocapillaris thickness and choriocapillaris flow simultaneously in young healthy subjects. It also suggested the structural importance of the choriocapillaris because the choriocapillaris thickness and flow were constant.

Conflicts of Interest

The authors declare no conflicts of interest relevant to this article.

References

1. Spaide RF, Koizumi H, Pozzoni MC. Enhanced depth imaging spectral-domain optical coherence tomography. *Am J Ophthalmol* 2008;146:496-500.
2. Margolis R, Spaide RF. A pilot study of enhanced depth imaging optical coherence tomography of the choroid in normal eyes. *Am J Ophthalmol* 2009;147:811-5.
3. Miyake M, Ooto S, Yamashiro K, et al. Pachychoroid neovascularopathy and age-related macular degeneration. *Sci Rep* 2015;5:16204.
4. Warrow DJ, Hoang QV, Freund KB. Pachychoroid pigment epitheliopathy. *Retina* 2013;33:1659-72.
5. Dansingani KK, Balaratnasingam C, Naysan J, Freund KB. En face imaging of pachychoroid spectrum disorders with swept-source optical coherence tomography. *Retina* 2016;36:499-516.
6. Pang CE, Freund KB. Pachychoroid neovascularopathy. *Retina* 2015;35:1-9.
7. Ramrattan RS, van der Schaft TL, Mooy CM, et al. Morphometric Analysis of Bruch's membrane, the choriocapillaris, and the choroid in aging. *Invest Ophthalmol Vis Sci* 1994;35:2857-64.
8. McLeod DS, Lutty GA. High-resolution histologic analysis of the human choroidal vasculature. *Invest Ophthalmol Vis Sci* 1994;35:3799-811.
9. Almeida DR, Zhang L, Chin EK, et al. Comparison of retinal and choriocapillaris thicknesses following sitting to supine transition in healthy individuals and patients with age-related macular degeneration. *JAMA Ophthalmol* 2015;133:297-303.
10. Esmaeelpour M, Ansari-Shahrezaei S, Glittenberg C, et al. Choroid, Haller's, and Sattler's layer thickness in intermediate age-related macular degeneration with and without fellow neovascular eyes. *Invest Ophthalmol Vis Sci* 2014;55:5074-80.
11. Tan CS, Ouyang Y, Ruiz H, Sadda SR. Diurnal variation of choroidal thickness in normal, healthy subjects measured by spectral domain optical coherence tomography. *Invest Ophthalmol Vis Sci* 2012;53:261-6.
12. Hirata M, Tsujikawa A, Matsumoto A, et al. Macular choroidal thickness and volume in normal subjects measured by swept-source optical coherence tomography. *Invest Ophthalmol Vis Sci* 2011;52:4971-8.

13. Spaide RF, Klancnik JM Jr, Cooney MJ. Retinal vascular layers imaged by fluorescein angiography and optical coherence tomography angiography. *JAMA Ophthalmol* 2015;133:45-50.
14. Spaide RF. Choriocapillaris flow features follow a power law distribution: implications for characterization and mechanisms of disease progression. *Am J Ophthalmol* 2016;170:58-67.
15. Al-Sheikh M, Falavarjani KG, Pfau M, et al. Quantitative features of the choriocapillaris in healthy individuals using swept-source optical coherence tomography angiography. *Ophthalmic Surg Lasers Imaging Retina* 2017;48:623-31.
16. Al-Sheikh M, Tepelus TC, Nazikyan T, Sadda SR. Repeatability of automated vessel density measurements using optical coherence tomography angiography. *Br J Ophthalmol* 2017;101:449-52.
17. Kim M, Kim SS, Koh HJ, Lee SC. Choroidal thickness, age, and refractive error in healthy Korean subjects. *Optom Vis Sci* 2014;91:491-6.
18. Ikuno Y, Kawaguchi K, Nouchi T, Yasuno Y. Choroidal thickness in healthy Japanese subjects. *Invest Ophthalmol Vis Sci* 2010;51:2173-6.
19. Wang Q, Chan S, Yang JY, et al. Vascular density in retina and choriocapillaris as measured by optical coherence tomography angiography. *Am J Ophthalmol* 2016;168:95-109.
20. Heidelberg Engineering. Spectralis hardware operating instructions. Technical Specifications 2007;22-5.